

# Update to Preparation Design and Clinical Concepts Using the LeSage Veneer Classification System

1

Brian P. LeSage

## Contents

1.1	Introduction.....	000
1.2	Orthodontics as an Interdisciplinary Approach.....	000
1.3	Prototypes, Digital Smile Design, and a Try in One Veneer Technique.....	000
1.4	Veneer Preparation.....	000
1.5	Proper Adhesion.....	000
1.6	Classifications of Veneer Preparations.....	000
1.6.1	CL-I.....	000
1.6.2	CL-II.....	000
1.6.3	CL-III.....	000
1.6.4	CL-IV.....	000
1.7	Case Studies.....	000
1.7.1	Case I Demonstrating the LeSage CL-II Veneer Preparation Design.....	000
1.7.2	Case II Demonstrating the LeSage CL-IV Veneer Preparation Design.....	000
1.8	Conclusion.....	000
	References.....	000

## 1.1 Introduction

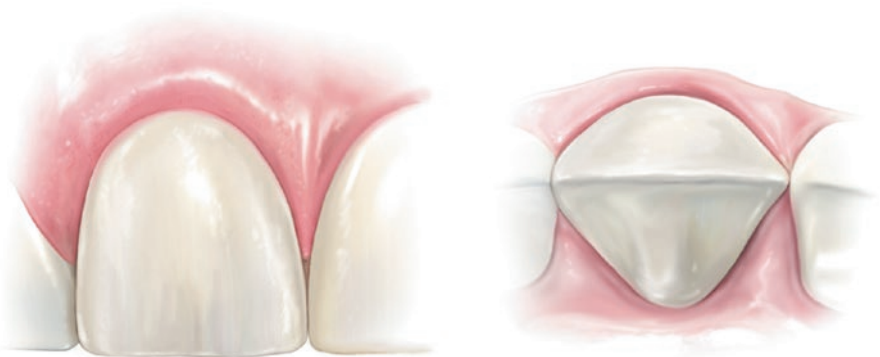
Porcelain veneers had long been considered to be only an esthetic solution. However, their range of indications has been steadily increasing, making ceramic veneers a highly viable alternative to classic, far more invasive forms of restorative treatment. Today, veneers can be used to handle esthetics (discolored teeth, fractured and worn teeth, diastemas, dental defects, etc.) and to restore the biomechanics of the dentition, as well as many other indications.

B. P. LeSage (✉)  
UCLA School of Dentistry, Los Angeles, CA, USA  
Beverly Hills Institute of Dental Esthetics, Beverly Hills, CA, USA

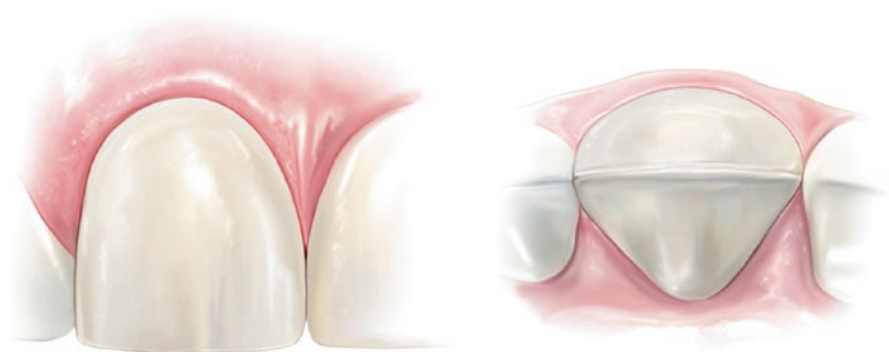
Historically, preparations for ceramic veneers have varied from extremely aggressive to a minimal reduction or a lack of preparation. The concept of no-preparation or minimal-preparation veneers is nearly 40 years old, but for decades there was no classification system categorizing the extent of preparation for different veneer treatments [1]. This lack of clear-cut guidelines for technical procedures and for case selection led to confusion and misunderstandings. The author proposed such a classification system in 2013, and in this chapter, the LeSage veneer classification system is expanded on and explained, and examples for implementing the system are presented. The author's veneer classification system published in 2013 is based on an assessment of the amount of enamel available and the amount of dentin exposed. This system benefits dentists, lab technicians, and patients, by assisting in diagnosis of various clinical scenarios and guiding conservative veneer preparation and placement [1].

Today, we are moving toward minimally invasive dentistry with the philosophy that less is more. Treating esthetic demands with noninvasive or minimally invasive techniques can preserve the natural tissues [2]. Less tooth reduction means better adhesion and clinical longevity. It is no longer acceptable to over-prepare teeth for convenience or lack of understanding of alternative treatments. In recent years, laboratory techniques have evolved to produce ultrathin ceramic veneers, which has increased the popularity of “no-prep” veneers [3]. This so-called “no-prep” approach has been described for more than 10 years in the literature [4–6] and ideologically reiterates the methodologies of when veneers were first introduced as conservative, additive restorative procedures for which slight or no preparations were required [7, 8]. When properly selected and managed, “no-prep” veneers can have biologically healthy and optically beautiful margins and emergence profiles, all supporting the biomimetic dental philosophy of tooth preservation and less amputation of tooth structure [9] (Figs. 1.1 and 1.2).

However, these days, it is no longer acceptable to limit veneer descriptions to no-prep or conventional all-ceramic designs. Explained in this chapter are two additional, distinct classifications that should aid dentists, lab technicians, and patients in their ability to provide better communication, consent, diagnosis, treatment planning, material selection, education, and tooth structure preservation.



**Fig. 1.1** Normal tooth contours from facial and occlusal views



**Fig. 1.2** “No-prep” veneer shown when indicated. In many clinical scenarios, adding volume will move line angles to the interproximal zone and make the tooth appear wider

It is important to consider veneers as part of the multidisciplinary field of restorative dentistry. In addition to the LeSage veneer classification system, this chapter also includes tips for ensuring the long-term success of veneers and patient satisfaction. These include the usage of prototypes, digital smile design, a try in one veneer technique, as well as proper preparation and adhesion protocol. Ultimately, clinician experience is the most important tool for determining appropriate treatment plans to address clinical concerns and patients’ esthetic demands [1, 10].

---

## 1.2 Orthodontics as an Interdisciplinary Approach

There are a variety of treatments and solutions that can be applied to move, straighten, and ultimately align your teeth. One of our goals is to limit the amount of tooth structure removal when placing veneers. Often, we can employ a minimally invasive interdisciplinary ortho-restorative treatment plan. Frequently, far less tooth structure is lost if orthodontic treatments are used to fix tooth alignment prior to placing veneers. Orthodontic treatment is a noninvasive modality for achieving desired results and/or ensuring teeth are properly positioned for long-term predictable function and esthetics.

For example, prominent gaps may require orthodontic treatment before the placement of veneers. Without orthodontic treatment, closing the gaps with veneers will result in creating the look of abnormally large teeth. Moderate to severe crowding may also require orthodontic treatment to align the teeth. If veneer treatment is carried out without orthodontic treatment, the rotated teeth will need to be heavily ground down to accommodate the veneers, weakening the teeth in the process and in some cases exposing the nerve. Similarly, a patient who presents with a narrow arch form may require orthodontics before the placement of veneers. The author uses Invisalign® approximately 50% of the time as a pre-prosthetic modality to prevent preparing beyond the dentinoenamel junction in the teeth. Providing esthetics, while accommodating for anterior guidance and eliminating working and nonworking interferences, is a key component of long-term orthodontic occlusal stability.

Interdisciplinary modalities may also include the following: perio-plastics, tooth bleaching, direct composite restorations, and porcelain veneers, which are options providing predictability and longevity in carefully selected esthetic cases [1, 11].

### 1.3 Prototypes, Digital Smile Design, and a Try in One Veneer Technique

Veneers have to be esthetically pleasing. There are multiple opportunities within the veneer placement process that we affirm, and reaffirm, the veneers are pleasing to the patient before solidifying the final treatment outcome. The patient likely has specific expectations, and there should be a test drive with provisional restorations to ensure proper esthetics and function prior to fabrication of the final veneers [12].

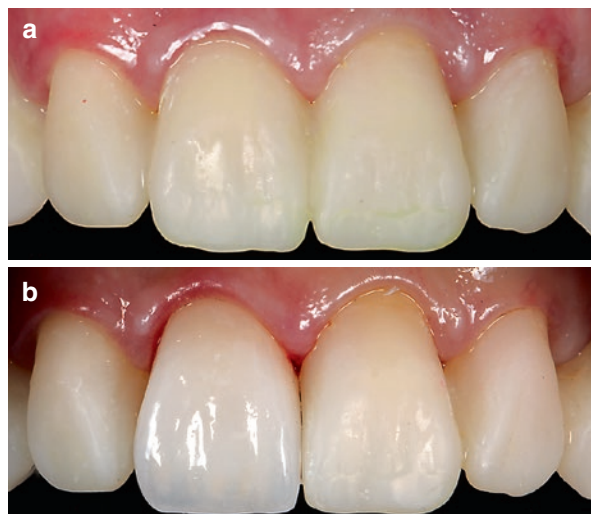It is common to create mock-ups, or temporary trial veneers, by taking impressions or by using CAD/CAM technology to make a mock-up digitally. The author prefers to make prototypes, which can be used for a significant amount of time, simulating the final outcome, allowing the patient to test esthetics, phonetics, and function. Bis-acryl resin temporary materials have become the material of choice for *esthetically driven* veneer prototypes due to excellent mechanical and optical properties, marginal adaptation, polishability, and favorable add-on properties [13].

Similarly, a digital smile design (DSD) can be used to increase the emotional commitment and consequently the rate of acceptance of your dental treatments through an emotional mock-up [14]. The DSD is a digital planning tool for esthetic dentistry, in which the evaluation of the esthetic relationship among the teeth, gingiva, smile, and face is obtained through lines and digital drawings that are inserted on the facial and intraoral photographs of the patient [15–18]. A bis-acryl temporary material is dispensed into the putty matrix to fill the facial surface. The filled matrix is inserted into the patient's mouth, the matrix is removed, and excess material is removed. It is common to then take photos or a short video of the patient for them to see the transformation. This full-face picture of them will increase satisfaction and emotional commitment to the final treatment plan.

While DSD presents some advantages, the author regards prototypes as an objective and efficient tool in treatment planning communication. They can be used to confirm the treatment plan before and/or after the final preparation, thereby evaluating the final restorations within the limitations of biological and functional considerations [5, 19].

The author now introduces into the literature the practice of the “try in one” (TIO) veneer technique. At the delivery appointment, one central incisor prototype is cut out and the definitive veneer is tried in. This single veneer should fit to place confirming the midline and the length of the definitive restorations (Fig. 1.3). Thus, the author's TIO technique confirms fit, length, contacts, and color. Trying in one veneer provides a reference point to prove that the length, shape, and shade are appropriate prior to cementing all the final restorations. This TIO technique is a useful process for reassuring the patient that all their esthetic parameters and expectations have been met and holding the dentist and ceramist accountable.

**Fig. 1.3** (a, b) “TIO technique” (a) Close-up of patient’s approved esthetically driven bis-acrylic prototypes demonstrating uniformity with variety (b) Definitive veneer #8 placed within existing prototypes to confirm length, width, and midline and hold all team members accountable



All of these processes build trust between the patient and dentist. They allow the patient to request changes throughout the process, so that they feel in control and satisfied with the final outcome.

## 1.4 Veneer Preparation

Expected veneer longevity depends on tooth preparation, which should ideally be confined to enamel and minimally involve proximal contact areas and functional considerations, such as occlusion [20]. It is also necessary to maintain the cervical enamel margin and incorporate the incisal edge to increase fracture resistance and enable proper placement [20]. To increase functional and esthetic properties of these restorations, proximal extensions should be created just beyond contact areas [20]. The clinical success of porcelain veneers depends upon many factors. Although dental and gingival structures play important roles in optical response and withstanding masticatory forces, dentists must consider and recreate many anatomical components while providing functional integrity [20].

One critical step in the preparation technique is the achievement of sufficient ceramic thickness [13]. While conducting their studies, researchers Shillingburg and Grace found that as patients age, the enamel thickness on the facial surfaces of anterior teeth decreases [21–23]. On the cervicofacial surface of the central incisor, 1 mm above the cemento-enamel junction, enamel thickness ranges from 0.17 mm to 0.52 mm, with a mean thickness of 0.31 mm [21–23]. The thickness on the mid-facial surface, 5 mm from the cemento-enamel junction, ranges from 0.45 mm to 0.93 mm, with a mean thickness of 0.75 mm [21–23]. The author used these tooth structure parameters as a framework for the LeSage veneer classification system and the author’s preferred Class I or Class II veneer preparation techniques. The

guidance provided in the LeSage classification system, informed by enamel thickness, allows for conservation of tooth structure and predictable minimally invasive veneer preparations.

The typical veneer preparation model is technique-sensitive and incorporates guidelines for achieving functional and esthetic results. When reducing the labial and proximal surfaces, there must be no less than 0.3–0.5 mm of room, and it should be uniform whenever possible [21, 24–29]. When going from thick to thin—as in a large Class IV incisal fracture or large Class III composite removal—a smooth transition must be incorporated. Extending the preparation interproximally to the mid-point of the papilla, parallel to the crown’s original form, is necessary to improve adhesion, conceal the margin, allow an accurate impression, and increase the overall veneer strength [21, 26, 29]. The decision to reduce the incisal edge should be based on whether there is a need to increase the tooth length and the labiolingual width of the incisal edge [21, 26, 29]. Since line angles are involved, rounded corners and edges must be established.

Veneers with an incisal butt margin usually demonstrate fracture loads similar to those of unprepared teeth [21, 30]. In these cases, the incisal edge may be reduced by up to 2 mm [21, 28, 31]. However, the preparation’s facial margin should ideally be chamfered and in enamel [21, 26, 28, 29, 32]. The interproximal and gingival margins of porcelain veneer restorations also must end in enamel at or above the free gingival margin or barely within the gingival sulcus when possible [21, 26, 29].

Techniques exist that allow for consistent tooth surface reduction while minimizing it [12, 33, 34]. Because traditional veneering approaches can lead to significant dentin exposure, strategies should be taken to limit preparations to the enamel [12, 13, 34]. Using an additive diagnostic procedure and silicone indexes avoids unnecessary dentin exposure, improves biomechanics and esthetics, and allows more predictable bonding [13].

Gürel et al. recently showed a 98.7% success rate of porcelain laminate veneers when the preparation depth is kept within the limits of enamel [35]. For misaligned teeth, a transparent silicon index can be used to prepare esthetic pre-evaluative temporaries to be used as a guideline to prepare the tooth structure. They resemble the exact final contours of the final outcome, such as the incisal edge position and the facial contours of the teeth; we can start by preparing the teeth 0.5 mm through the mock-up as if we were dealing with a simple case in which the teeth are aligned properly [36]. Once teeth are prepped according to their limitations, adhesion protocols can commence.

---

## 1.5 Proper Adhesion

The enamel bond is beyond reproach and is the strongest, least invasive, most conservative, and most predictable bond available. Enamel bonding mimics the dento-enamel junction or the natural bond between enamel and dentin [37]. The same cannot be said about bonding to the dentin. However, even bonding to dentin is favored over nonadhesive approaches [38]. The “gold standard” remains total-etch three-step systems or three-step etch and rinse [38–40].

There remain many issues to consider before bonding to dentin [21]. For example, adhesion more often fails at the dentin–cement interface [21, 41]. Also, micro-leakage typically occurs between the dentin and cement, leaving underlying dentin unprotected [21, 41]. Studies show that the bond strength of resin cements to dentin is much lower than bonds to enamel, which is why maintaining an enamel periphery is essential [21, 41–45].

The ideal scenario is to keep the bond completely in enamel. Of utmost importance and when properly prepared, enamel substrates provide the most predictable surface to bond porcelain [1, 46–49]. The micro-retentive adhesion of porcelain to enamel has been well-documented for more than 20 years [1, 30, 46]. In a longitudinal study with a 12-year follow-up, ceramic veneers cemented on enamel showed significantly higher clinical longevity than those cemented on dentin, with success rates of 98.7% and 68.1%, respectively [50].

Unaffected by lingual preparation design, porcelain veneers adhesively bonded to enamel demonstrate the greatest long-term success rates, making no-preparation veneers the treatment of choice when indicated [1, 46–49]. When dentin is involved, an enamel periphery is preferable for predictability [1, 30, 46]. When less than 50% of enamel periphery and less than 50% enamel remain, discussion with the patient about limitations and predictability of the outcome is necessary [1, 10, 46]. Given these conditions—50% or more enamel on the tooth is required and 50% or more of the bonded substrate is on the enamel—70% or more of the margin must be enamel. The condition or integrity of the substrate to which veneers will be bonded is also important for success [51–53].

Veneer cementation is fundamental; it should be done with extreme care. It is important to remember that, unlike conventional crowns, which use dual-cured resin cements, ceramic laminates should use a purely light-cured luting agent to prevent the color shifts that can occur due to chemical changes in the curing process [54]. Absolute isolation during cementation procedures is essential for bond maintenance, which ultimately protects the internal surface of the restoration and is necessary for longevity [52, 53].

---

## 1.6 Classifications of Veneer Preparations

Referred to as no, minimal, or conventional preparation, veneer classifications—or lack thereof—create a large gray zone of misunderstanding and miscommunication with patients and within the dental profession. Left unanswered, questions regarding tooth structure removal, finish lines and margins, and other aspects can cause confusion in practice.

Flaws and inaccuracies in previously proposed preparation guidelines make those guidelines irrelevant [55]. To dissolve uncertainty, this veneer classification system was proposed to aid with diagnosis, treatment planning, patient education, consent and understanding, and communication among dental team members, and to provide viable solutions to public requests for elective procedures.



Defined as the way something is categorized, labeled, organized, distinguished, arranged, or sorted, classification adds clarity. Dentistry has distinguished Class I through Class V classifications in operative dentistry; there are inlays, onlays (3/4 and 7/8), and full-coverage crowns in prosthodontics. Classifications exist for furcations in periodontics; lip lines; bone quality; LeForte's CL-I, CL-II, and CL-III in orthodontics; removable prosthesis cantilevers; and bone/crest levels. In 1974, Talim and Gohil classified tooth cracks and fractures in endodontics, and Misch classified implant prostheses for patients; in 2009, McLaren classified ceramics [52]. Since classification systems have infiltrated so many aspects of life, veneers should be no different.

In the absence of widely advocated porcelain veneer tooth preparation guidelines, Tables 1.1 and 1.2 show the basis for the LeSage veneer classification system. The system was introduced to clarify the aforementioned gray zone between classic conventional veneer preparation and no- or minimal-preparation veneers. This metric provides an accurate measurement system for quantifying tooth structure removal on a case-by-case basis [56]. Studies show that when a conservative approach is taken and significant tooth structure remains, dentists can provide patients with a better prognosis for the restored teeth [56].

The LeSage veneer classification system divides preparation and veneering into reduction (referred to as space requirement, working thickness, or material room), volume of enamel remaining, and percentage of dentin exposed. Notably, classifications I, II—both of which incorporate addition veneers—and III require 70% to 100% enamel periphery.

**Table 1.1** Basis for the LeSage veneer classification system (dentin exposed)

Reduction	Facial	Dentin exposed
<b>CL-I</b> No-prep or practically prep-less	Detectable with magnification, with or without gingival finish lines	0 <sup>a</sup>
<b>CL-II</b> Modified prep-less or minimally invasive	Up to 0.5 mm	10–20% <sup>a</sup>
<b>CL-III</b> Conservative design	0.5–1 mm	20–50% <sup>a</sup>
<b>CL-IV</b> Conventional all-ceramic design	1+ mm	50%

<sup>a</sup>Enamel periphery of at least 70%

**Table 1.2** Basis for the LeSage veneer classification system (enamel remaining)

Reduction	Facial	Enamel remaining
<b>CL-I</b> No-prep or practically prep-less	Detectable with magnification, with or without gingival finish lines	95–100%
<b>CL-II</b> Modified prep-less or minimally invasive	Up to 0.5 mm	80–95%
<b>CL-III</b> Conservative design	0.5–1 mm	50–80%
<b>CL-IV</b> Conventional all-ceramic design	1+ mm	<50%



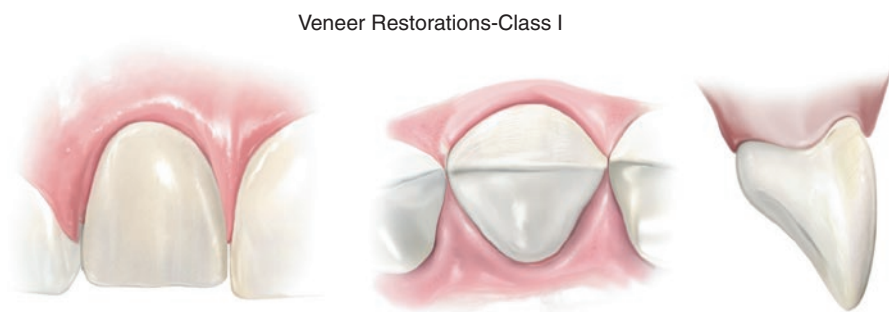### 1.6.1 CL-I

CL-I is the purest form of *no-preparation* or *practically prep-less* veneers but can include a discreet finish line or only a loupe-detectable margin (Fig. 1.4). The term *addition veneers* frequently describes this preparation design today. In this classification, 95–100% of enamel volume remains after preparation, and no dentin is exposed. Ideal whenever possible, preparation must be completely and only in enamel.

This preparation type can be easily achieved using a bis-acrylic preparation guide created from a putty or silicone matrix of the diagnostic wax-up, which can be applied to the teeth [55]. Depth cuts of 0.5 mm for CL-I are placed into the incisal and facial aspects of the bis-acrylic preparation guide, which should result in the depth-cutting bur not touching the tooth, and the clinician should consider removing the aprismatic enamel and placing a practically undetectable finish line to aid ceramists in determining margin placement. These depth-cutting grooves minimize potential for over-preparation.

Many times considered the best option because of their tooth structure preservation qualities, prep-less veneers have limitations, including esthetic outcomes. Calamia found that veneers placed with no preparation resulted in periodontal problems as a result of over-contoured teeth that changed the emergence profile [1, 46, 57]. It was concluded, however, that the veneer treatment modality would function long term [1, 46, 49]. To correct the emergence issue, a 0.5-mm reduction restored by 0.5 mm of porcelain provided nearly the original tooth profile with the veneer in place [1, 46]. Additionally, it was discovered that wrapping the incisal edge enhances strength and that preparations limited to the facial surface only were not as strong as those with a wrapped incisal edge [1, 31, 46]. This latter veneer preparation type is described below as CL-II.

Some indications for no-prep veneers include peg laterals, genetic anomalies producing smaller teeth, short and worn teeth, orthodontics leading to a narrow arch, and patients with larger lips. Disadvantages may include limited shade alteration capability, difficulty developing the correct axial inclination, proportional errors, and trouble forming the proper gingival symmetry [1, 46, 58].



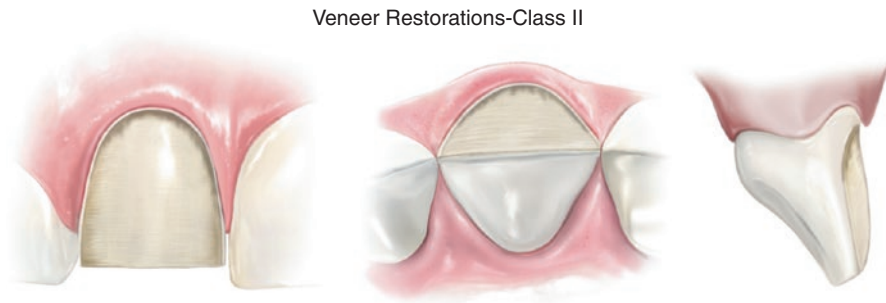
**Fig. 1.4** Illustration demonstrating LeSage Class I veneer preparations requiring little to no tooth structure removal. Facial reduction allowing for 95–100% of the enamel remaining and no dentin should be exposed

### 1.6.2 CL-II

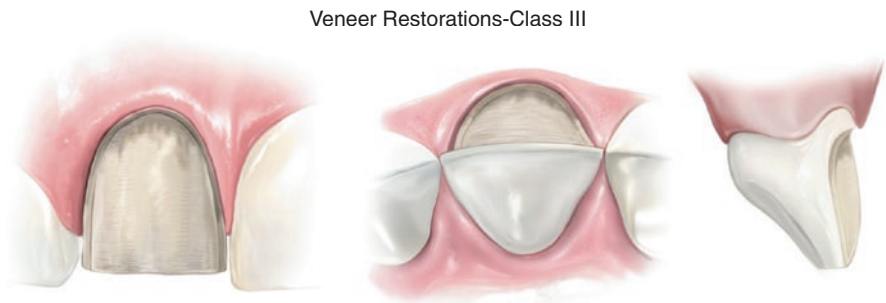CL-II deals with *minimally invasive* or *modified prep-less* veneers (Fig. 1.5). Addition veneers also may fall in this classification. This category should exhibit 80–95% volume of remaining enamel, 10–20% exposed dentin, and up to 0.5 mm of reduction. Ideally, CL-II veneers would have complete enamel periphery but may involve a small zone on the gingival margin consisting of dentin to clearly establish the restoration margins [59]. Additionally, 5–15% of dentin may be exposed on any facial surface (i.e., mesial, distal, or gingival), depending on veneer rotation. To complete a CL-II preparation, a bis-acrylic preparation guide, as previously described, can be used. An example of a CL-II prep will be discussed in the following section.

### 1.6.3 CL-III

CL-III is a *conservative preparation* classification (Fig. 1.6) and described as 60–80% enamel volume remaining, 20–40% dentin exposed, and 0.5–1 mm of



**Fig. 1.5** Illustration demonstrating LeSage Class II veneer preparations requiring a modified design. Facial reduction should be less than 0.5 mm, 80–95% of the enamel should remain, and 10–20% of the dentin can be exposed. (Brown in illustration is exposed dentin)



**Fig. 1.6** Illustration demonstrating LeSage Class III veneer preparation design requiring some “conservative” reduction. Facial reduction is 0.5–1 mm, the enamel remaining should be 50–80%, and dentin exposure is maximized at 50%

reduction. With more room for restorative material, the gingival margin will typically involve more dentin [59]. However, greater than 70–80% of the finish line must still be in enamel.

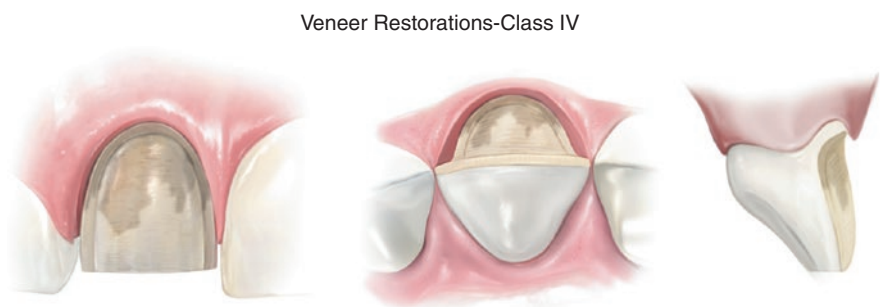#### 1.6.4 CL-IV

CL-IV is a *full veneer* or *conventional all-ceramic* design (Fig. 1.7) and is best described as approximately 50% of enamel volume remaining, greater than 40% of exposed dentin, and 1 mm or more of reduction. The peripheral margin may consist of only 50–70% enamel. Although this veneer preparation type has become an almost universally accepted technique for placing full veneers, functional and esthetic limitations remain—including lower fracture loads and decreased marginal integrity that ultimately lead to restorative failure [60, 61]. Preparation design and fatigue influence the marginal accuracy of veneers bonded to maxillary central incisors, with significantly higher marginal gap formations developing in complete veneer preparations [60, 61]. Therefore, all limits of restorative options should be considered before undertaking this procedure. A case study of a CL-IV prep will be discussed in the following section.

Any given patient could exhibit any combination of classifications due to acidic erosion, genetics, restorative material requirements, occlusion, or tooth- and arch-size discrepancies. As in periodontics, one tooth can be a CL-I furcation and a CL-III in the same dentition, and each has differing treatment approaches, prognosis, and varying care. Again, this veneer classification system was designed to help clarify professional communication and allow patients to better understand how much tooth structure will need to be removed. Such information will enable better informed consent, with patients making the choices they see fit.

When preparations fall outside these parameters, a crown should be *considered* for predictability and longevity.

It is well established that when a tooth has greater than 50% of enamel missing, moderate sclerotic dentin, and greater than 3 mm of unsupported porcelain, a crown must be considered. Magne found that 65% of a tooth's integrity comes from the



**Fig. 1.7** Illustrations demonstrating LeSage Class IV veneer preparations, considering conventional preparations. Facial reduction is typically greater than 1 mm, with less than 50% of enamel remaining and greater than 50% of dentin exposed

cingulum and approximately 27% from lingual marginal ridges [62, 63]. These anatomical landmarks must be preserved at all costs [64]. No significant differences in crown flexure were found between natural and veneered incisors when the cingulum is preserved [64].

However, clinical decisions must be based on the dentist's clinical experience, scientific data, evidence-based literature, the clinical scenario, the patient's desires (i.e., time and money considerations), and full consent based on knowledge of advantages, disadvantages, risks, benefits, and prognosis. These factors are significant in treatment selection. CL-I veneer preparation with its 100% enamel substrate is more predictable than CL-IV with its significant dentin exposure.

---


## 1.7 Case Studies

### 1.7.1 Case I Demonstrating the LeSage CL-II Veneer Preparation Design

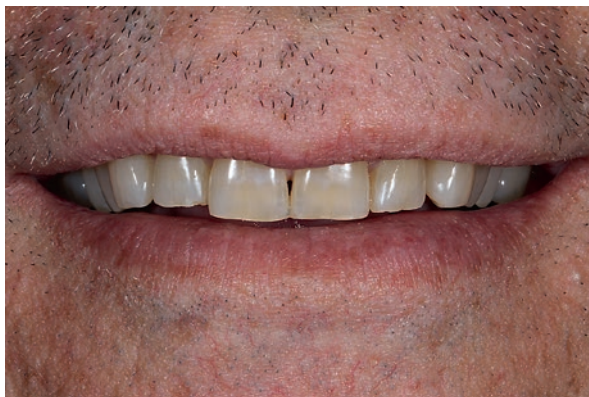Patient is a 62-year-old male who wanted a better color to his teeth and to show more teeth by adding length and width to his smile. The pre-op images show the dark color, deficient vestibular reveal, chipped incisal edges, and damage to his dentition due to parafunctional habits (Figs. 1.8 and 1.9). The goal was to create a pleasing smile with minimal tooth reduction, while maintaining good health.

A full mouth series of X-rays showed minor tooth decay indicating replacement of an existing crown and several simple composites prior to analyzing his dentition for

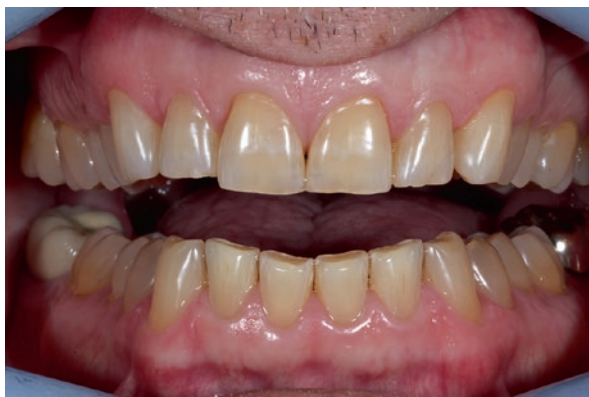**Fig. 1.8** Full-face pre-op of patient before orthodontic care and all-ceramic restorations on maxillary and mandibular teeth in the esthetic zone



**Fig. 1.9** Smile view pre-op showing patient's chief complaint, "I would like a better color to my teeth and want to show more teeth when I smile"



**Fig. 1.10** Retracted view pre-op showing damage to lower teeth with exposed dentin and dark, aged color to dentition




veneers. A diagnostic workup was performed with facebow transfer and centric relation mounted study models on a semi-adjustable articulator (SAM-3, Great Lakes, Tonawanda, NY) and diagnostic photographs. It revealed the need for orthodontic treatment to widen the arch and reposition the maxillary and mandibular teeth into more ideal anterior relationship to create a more protective occlusal scheme and not prepare past the dento-enamel junction. The incisal edges in both arches had exposed dentin which needed to be covered for long-term stability (Fig. 1.10).

After approximately a 1-year course of Invisalign (Figs. 1.11 and 1.12), a new series of diagnostic models were mounted on the SAM-3 articulator, diagnostic photos retaken, and a diagnostic wax-up completed (Fig. 1.13). Minor occlusal equilibration to eliminate any CO-MIP slide and gain immediate anterior disclusion was performed prior to starting the smile makeover.

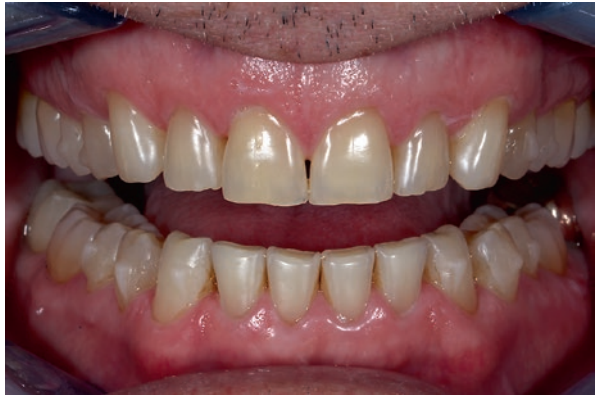Luxatemp (DMG, Ridgefield Park, NJ) bis-acryl, using the preparation guide introduced by Drs. Magne and Gürel, was applied to the teeth using a putty matrix fabricated from the diagnostic mock-up (Fig. 1.14) [13, 36]. Depth-cutting grooves of 0.5 mm were placed in the bis-acrylic material minimizing the depth and thus also minimizing the amount of enamel removal on each tooth (Figs. 1.15 and 1.16).



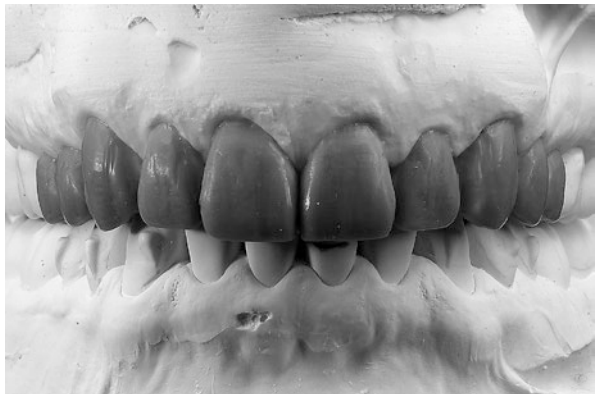**Fig. 1.11** Full face of patient after Invisalign treatment. Notice fuller buccal corridor



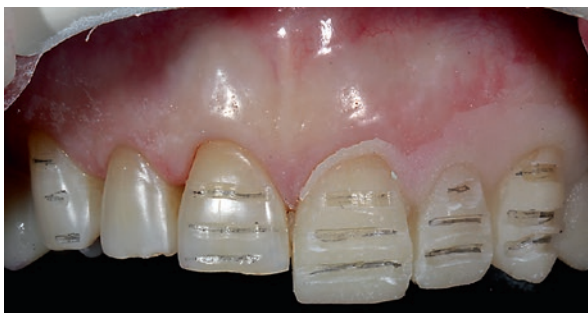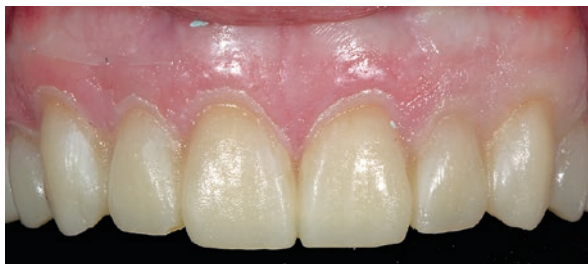**Fig. 1.12** Retracted frontal view showing wider arch and better alignment of teeth after Invisalign



**Fig. 1.13** Wax-up of maxillary teeth #4–13 on articulator working out esthetics and function

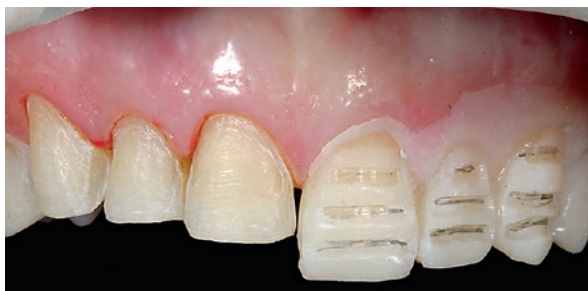

**Fig. 1.14** Custom preparatory guide placing bis-acrylic on teeth to be restored



**Fig. 1.15** 0.5 mm grooves placed into bis-acrylic. On patient's right the bis-acrylic has been removed, and visible is the less than 0.5 mm groove remaining to guide a minimal preparation of the final restorations. Note the incisal edges of the teeth #6–8 and the facial of tooth #7 were not even touched with the depth-cutting bur guides

**Fig. 1.16** Preparation of teeth #4–8 showing minimal dentin exposure—LeSage Class II veneer preparation design. Minor troughing visible after electrosurgery unit as a means for retraction

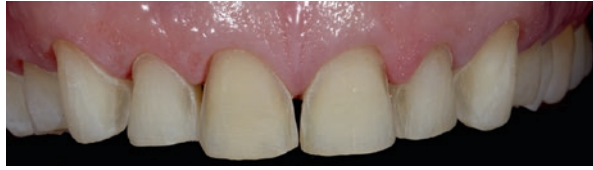

This modified prep-less veneer preparation technique will almost guarantee the authors preferred LeSage veneer CL-II preparation design: maintaining the preparation in 95% enamel and a 0.1 mm interproximal separation of the prepared teeth at its narrowest point (Fig. 1.17). To aid with shade communication including the ceramist, properly exposed images with the appropriate shade tabs are taken (Fig. 1.18).

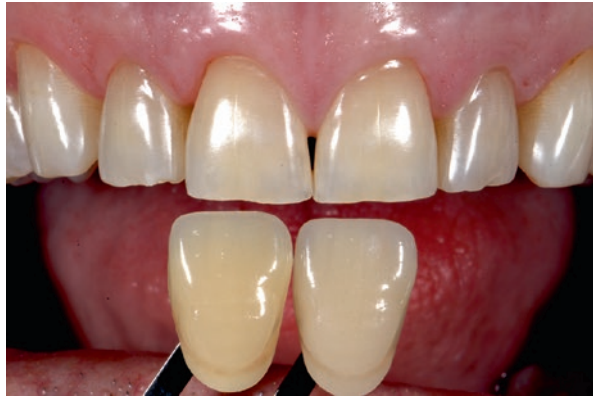An easy and effective way for patient visualization of their new smile design and final outcome is in fabricating prototypes, also known as temporaries or provisionals. These prototypes are created to the specifications of the anticipated definitive restorations, used to test and verify that the desired esthetic and functional outcomes are met.



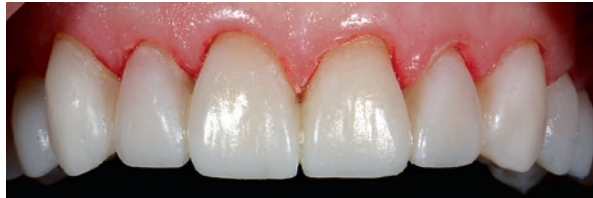**Fig. 1.17** Minimal preparation to teeth #4–13, confined primarily in enamel



**Fig. 1.18** Shade tab photo taken prior to dehydration of dentition. This is one of the multiple images taken to communicate chroma and value of the teeth and final restorations to the ceramist



**Fig. 1.19** Prototypes immediately finished and polished in the mouth

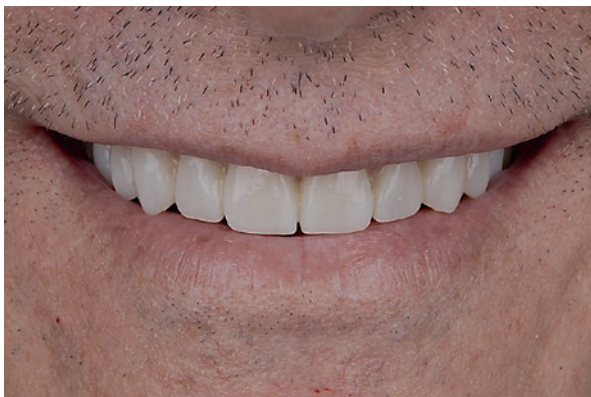

Prototypes were fabricated using the “shrink wrap” technique; bis-acrylic was placed in the putty matrix and allowed to self-cure set in the mouth. This allows the prototypes to shrink and lock between the teeth and onto the teeth (Fig. 1.19). Prototypes are worn until the patient expresses complete satisfaction with their smile makeover (Figs. 1.20 and 1.21). Patient’s approval of the prototypes is essential prior to the ceramist fabricating the veneers.

The Geller model poured from a PVS impression shows the removable dies and the stone papilla form and gingival tissues (Fig. 1.22). An incisal putty matrix from the model of the approved prototype aids the ceramist in fabricating predictable definitive restorations. Shown are the definitive feldspathic restorations on the Geller model (Fig. 1.23) and a mirror (Fig. 1.24).

The first step at the delivery appointment is the TIO technique; one central incisor prototype is cut out and the definitive veneer is tried in. This single

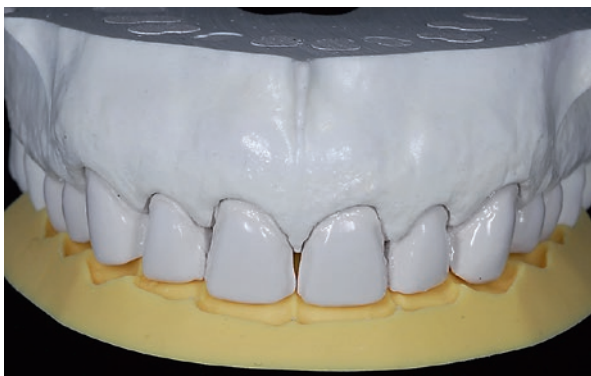**Fig. 1.20** Smile view showing prototypes/temporaries to trial esthetics and function



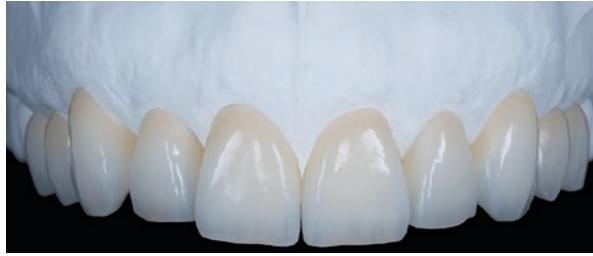**Fig. 1.21** Full face with prototypes trialing midline, smile line, incisal edge position, arrangement, and composition



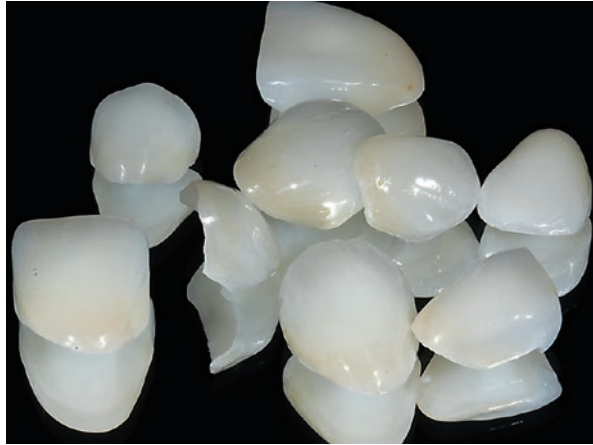**Fig. 1.22** Geller models showing removable dyes and stone papilla. Putty matrix from approved prototype to aid ceramist with length, midline, and incisal edge effects



**Fig. 1.23** Definitive restorations on Geller model



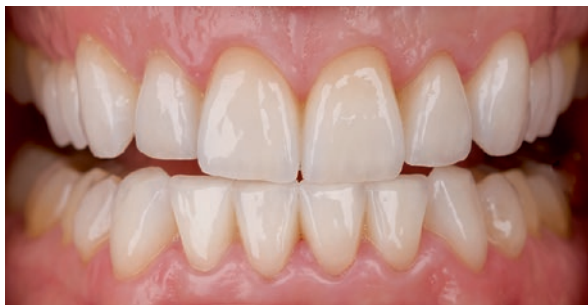**Fig. 1.24** Minimal thickness veneers showing polychromaticity



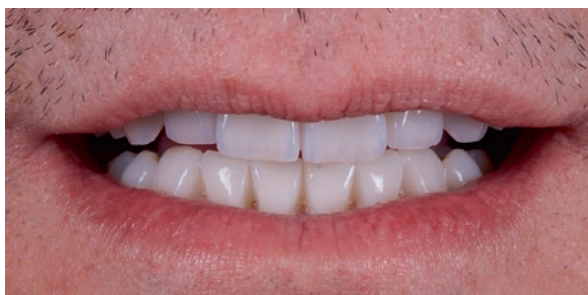veneer should fit to place confirming the midline and the length of the definitive restorations. Once fit and esthetics are confirmed by the clinician and approved by the patient in the authors' TIO technique, the remaining prototypes are removed. The tooth preparations were cleaned and all final veneers were tried in for approval by the patient. Once approved, the cementation process began.

Following the proper adhesion protocol is essential to the long-term success of the restoration. With proper isolation, the preparations were cleaned, etched, rinsed, and partially dried. The strong adhesion of porcelain to enamel is one of the primary reasons that no-prep (LeSage CL-I) and minimally prep veneers (LeSage CL-II) are the treatment option of choice when indicated. The primer was then applied and agitated for 30 s, air-dried, and light cured. Resin adhesive was placed on tooth and light-cured resin cement on the intaglio surface of the veneer. Bonding the definitive feldspathic restorations to an enamel substrate allows for the most predictable bond strengths, which directly correlate to clinical longevity [65]. The veneers were seated, light pressure was applied, and excess cement was wiped from the margins. The shade of the veneer and thickness of the porcelain material help to guide the curing time.

**Fig. 1.25** Retracted view of final layered feldspathic restorations showing natural progression of shades, perfect imperfections in size, axial inclination, and arrangement



**Fig. 1.26** Close-up view showing lowers also restored to address functional issues



The same technique was used on the mandibular veneers. A dual “E” appliance was fabricated to maintain and protect the patients bite and restorations. The restorations in the retracted view (Fig. 1.25), relaxed lip position (Fig. 1.26), and full face (Fig. 1.27) show the reestablishment of canine guidance, the protection of the exposed dentin, and the patients pleasing smile makeover.

### 1.7.2 Case II Demonstrating the LeSage CL-IV Veneer Preparation Design

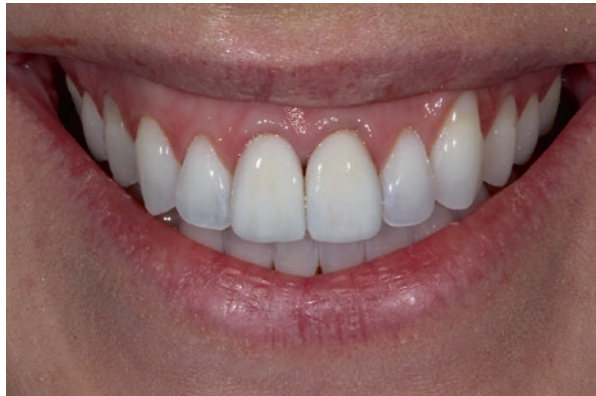This case involves a 31-year-old patient who wanted a better match in translucency and color in replacing the veneers on teeth numbers 8 and 9, placed approximately 10 years ago. Existing veneers were too opaque and thus appear lifeless in the mouth. The patient wanted to whiten the remaining dentition and create veneers with esthetically pleasing color and translucency.

Visual tension was present (Figs. 1.28 and 1.29). The restored central incisors had a very rectangular shape, long connector, and gingival health issues. In the full-face relaxed lip position view (Fig. 1.30), the facial and dental midline coincides, and nearly 4 mm of tooth reveal was present. The patient had a mild case of bruxism

**Fig. 1.27** Full face with minimally preparation all-ceramic restorations



**Fig. 1.28** Smile view showing visual tension in her smile. Veneers on teeth #8 and 9

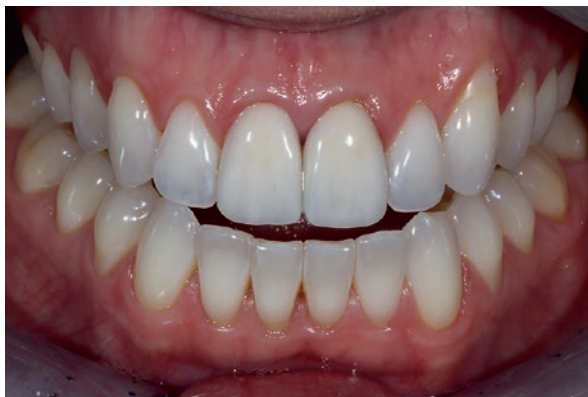

but expressed a commitment to avoiding any unnecessary function or load on the restorations. Using the patient's signs and symptoms, and the patient's preferences, will assist with the new smile design to create the appropriate length, midline, outline form, color, and translucency.

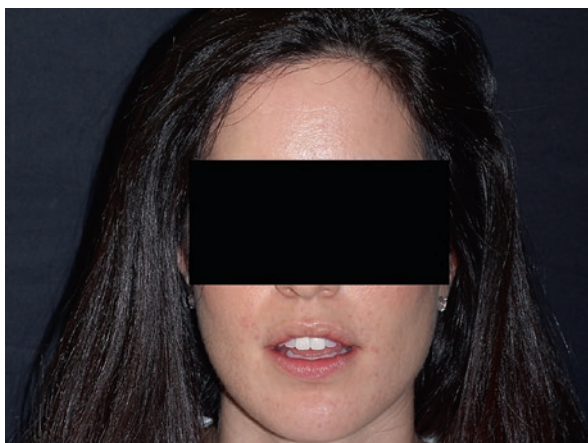Treatment started in a periodontist's office by performing scaling and root planing of the maxillary sextant. The veneers were then carefully cut off using a coarse diamond (# 6466-020, Brasseler, Savannah, GA). Besides ensuring a definitive margin and removing all cement for maximum bond strength, no additional tooth



**Fig. 1.29** Retracted view—preoperative. Notice opacity and lack of translucency to veneers and long connector



**Fig. 1.30** Relaxed lip position—preoperative

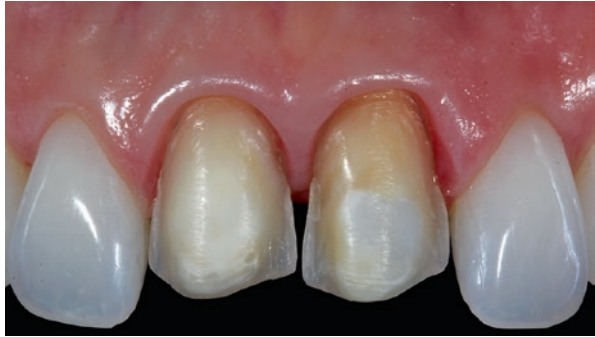

prep was performed. The preparation was a LeSage CL-IV, the least-predictable bond, as seen many times in replacement veneers, with greater than 50% dentin exposed and at best 50% of margin in enamel. CL-IV is the least-predictable bond. Therefore, patients should be properly informed and given all treatment options. The stump shade, even after internal bleaching with sodium perborate, affects the restorative material selection and porcelain layering technique (Fig. 1.31).

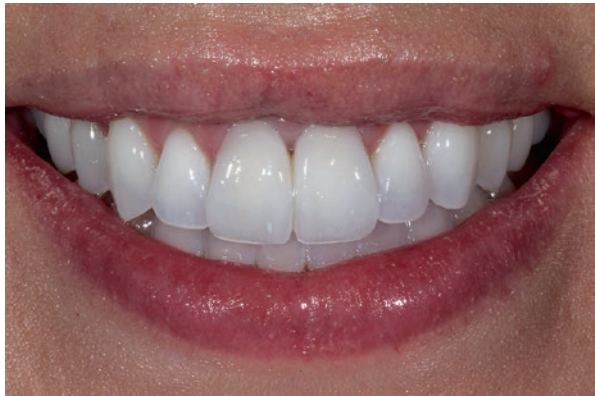Lab-fabricated prototypes made with acrylic were used to guide the gingival healing and papilla formation. The prototypes' goal is to mimic the natural esthetics of color, translucency, contour, embrasures, composition, and arrangements (Fig. 1.32). These prototypes were worn for 4 months prior to approval by the patient (Fig. 1.33).

The definitive feldspathic veneers were delivered using a total-etch, three-step system adhesive and resin cement. The relaxed lip position smile (Fig. 1.34) shows the translucency, harmony, and balance the patient desired.

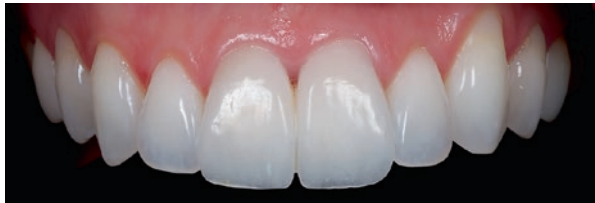**Fig. 1.31** Remove veneers on teeth #8 and 9 and refine preparations. Typical LeSage Class IV veneer preparation design as seen in most re-treatment cases



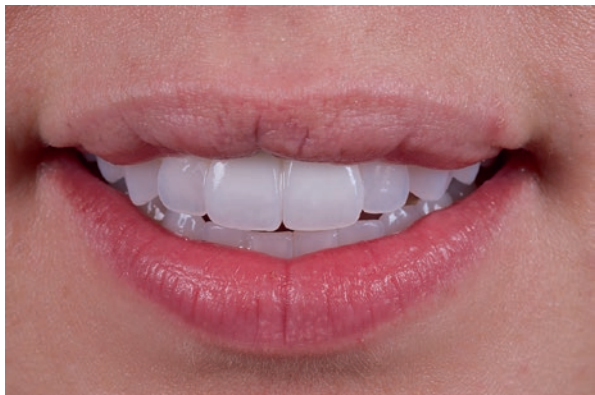**Fig. 1.32** Smile view with prototypes. Notice gingival health, pleasing translucency, and outline form



**Fig. 1.33** Retracted view of prototypes. Gingival embrasure properly contoured to allow for gingival ingrowth



**Fig. 1.34** Definitive all-ceramic restorations showing natural harmony and balance to patient's smile





## 1.8 Conclusion

Dentistry has sound, indisputable evidence affirming adhesive dentistry as the most conservative, least invasive, and most predictable way to restore teeth to normal form, function, strength, and optical properties when tooth-colored materials are used. Additionally, adhesive dentistry preserves the greatest amount of tooth structure, while satisfying patients' restorative and esthetic needs [1, 11, 66]. Clinicians must stay abreast of material selection, adhesive protocol, and scientific advances.

Before considering available smile-enhancing options, patients should undergo comprehensive clinical examinations, including an esthetic and functional evaluation [1, 11]. Ultimately, success is measured using the functional and esthetic parameters desired by the patient and required by the dentist.

More clinical evidence is needed to provide the standard of care required to comply with and support nonmaleficence [1, 67]. From Latin *praedicius* or *praedicere*, meaning to know beforehand, the term “predictability” suggests that dentistry should develop models that dentists can follow to provide predictable comprehensive esthetic outcomes. The LeSage veneer classification system enables dentists to improve the quality of their dental treatment and give patients the best in function, longevity, and esthetics.

The author would like to acknowledge the ceramic work of Michel Magne MDT of Beverly Hills Dental Laboratory, Inc. Oral Design Los Angeles.

---

## References

1. LeSage BP. Establishing a classification system and criteria for veneer preparations. *Compend Contin Educ Dent*. 2013;34(2):104–12.
2. Bahadır HS, Karadağ G, Bayraktar Y. Minimally invasive approach for improving anterior dental aesthetics: case report with 1-year follow-up. *Case Rep Dent*. 2018;2018:4601795.
3. Farias-Neto A, Dantas de Medeiros FC, Vilanova L, Chaves MS, de Araújo JFF B. Tooth preparation for ceramic veneers: why less is more. *Int J Esthet Dent*. 2019;14:156–64.
4. Mizrachi M, Lowe RA. A new and economical concept no-prep veneers. *Dent Today*. 2011;30:138–43.
5. Gürel G, Wells D. Low-risk dentistry using additive-only (“no-prep”) porcelain veneers. *Compend Contin Educ Dent*. 2011;32(5):50.
6. Freyberg BK. No-prep veneers: the myths. *Dent Today*. 2011;30(6):70–1.
7. Calamia JR. Etched porcelain facial veneers: a new treatment modality based on scientific and clinical evidence. *N Y J Dent*. 1983;53:255–9.
8. Calamia JR. Etched porcelain veneers: the current state of the art. *Quintessence Int*. 1985;16(1):5–12.
9. D’Arcangelo C, Vadini M, D’Amario M, Chiavaroli Z, De Angelis F. Protocol for a new concept of no-prep ultrathin ceramic veneers. *J Esthet Restor Dent*. 2018;30:173–9.
10. Calamia JR. Clinical evaluation of etched porcelain veneer. *Am J Dent*. 1989;2(1):9–15.
11. Strassler HE. Minimally invasive porcelain veneers: indications for a conservative esthetic dentistry treatment modality. *Gen Dent*. 2007;55(7):686–96.
12. Magne P, Magne M. Use of additive waxup and direct intraoral mock-up for enamel preservation with porcelain laminate veneers. *Eur J Esthet Dent*. 2006;1(1):10–9.
13. Magne P, Belser UC. Novel porcelain laminate preparation approach driven by a diagnostic mock-up. *J Esthet Restor Dent*. 2004;16(1):7–16.
14. Coachman C, Calamita M. Digital smile design: a tool for treatment planning and communication in esthetic dentistry. *Quintessence Dent. Technol*. 2012;35:103–111.

15. Meereis CT, de Souza GB, Albino LG, Ogliari FA, Piva E, Lima GS, et al. Digital smile design for computer-assisted esthetic rehabilitation: two-year follow-up. *Oper Dent.* 2016;41:E13–22.
16. Miranda ME, Olivieri KA, Rigolin FJ, de Vasconcellos AA. Esthetic challenges in rehabilitating the anterior maxilla: a case report. *Oper Dent.* 2016;41:2–7.
17. Lin WS, Zandinejad A, Metz MJ, Harris BT, Morton D. Predictable restorative work flow for computer-aided design/computer-aided manufacture-fabricated ceramic veneers utilizing a virtual smile design principle. *Oper Dent.* 2015;40:357–63.
18. Cooper LF, Culp L, Luedin N. A digital approach to improved overdentures for the adolescent oligodontia patient. *J Esthet Restor Dent.* 2016;28:144–56.
19. Reshad M, Cascione D, Magne P. Diagnostic mock-ups as an objective tool for predictable outcomes with porcelain laminate veneers in esthetically demanding patients: a clinical report. *J Prosthet Dent.* 2008;99:333–9.
20. Mangini F, Cerutti A, Putignano A, et al. Clinical approach to anterior adhesive restorations using resin composite veneers. *Eur J Esthet Dent.* 2007;2(2):188–209.
21. Jacobson N, Frank CA. The myth of instant orthodontics: an ethical quandary. *J Am Dent Assoc.* 2008;139(4):424–34.
22. Shillingburg HT Jr, Grace CS. Thickness of enamel and dentin. *J South Calif Dent Assoc.* 1973;41(1):33–6.
23. Atsu SS, Aka PS, Kucukesmen HC, et al. Age-related changes in tooth enamel as measured by electron microscopy: implications for porcelain laminate veneers. *J Prosthet Dent.* 2005;94(4):336–41.
24. Magne P, Douglas WH. Additive contour of porcelain veneers: a key element in enamel preservation, adhesion, and esthetics for aging dentition. *J Adhes Dent.* 1999;1(1):81–92.
25. Ferrari M, Patroni S, Balleri P. Measurement of enamel thickness in relation to reduction for etched laminate veneers. *Int J Periodontics Restorative Dent.* 1992;12(5):407–13.
26. Garber DA. Rational tooth preparation for porcelain veneers. *Compendium.* 1991;12(5):316–20.
27. Kois JC, McGowan S. Diagnostically generated anterior tooth preparation for adhesively retained porcelain restorations: rationale and technique. *J Calif Dent Assoc.* 2004;32(2):161–6.
28. Friedman MJ. Porcelain veneer restorations: a clinician's opinion about a disturbing trend. *J Esthet Restor Dent.* 2001;13(5):318–27.
29. Garber DA. Porcelain laminate veneers: ten years later. Part i: tooth preparation. *J Esthet Dent.* 1993;5(2):56–62.
30. De Munck J, Van Landuyt K, Peumans M, et al. A critical review of the durability of adhesion to tooth tissue: methods and results. *J Dent Res.* 2005;84(2):118–32.
31. Castelnovo J, Tjan AH, Phillips K, et al. Fracture load and mode of failure of ceramic veneers with different preparations. *J Prosthet Dent.* 2000;83(2):171–80.
32. Brunton PA, Aminian A, Wilson NH. Tooth preparation techniques for porcelain laminate veneers. *Br Dent J.* 2000;189(5):260–2.
33. Cherukara GP, Davis GR, Seymour KG, et al. Dentin exposure in tooth preparations for porcelain veneers: a pilot study. *J Prosthet Dent.* 2005;94(5):414–20.
34. Gürel G. Porcelain laminate veneers: minimal tooth preparation by design. *Dent Clin N Am.* 2007;51(2):419–31.
35. Gürel G, Morimoto S, Calamita MA, et al. Clinical performance of porcelain laminate veneers: outcomes of the aesthetic pre-evaluative temporary (APT) technique. *Int J Periodontics Restorative Dent.* 2012;32:625–35.
36. Gürel G. The science and art of porcelain laminate veneers. *Quintessence.* 2003;7:246.
37. Magne P. Composite resins and bonded porcelain: the Postamalgam era? *Resins Porcelain.* 2006;34(2):135–47.
38. Van Meerbeek B, De Munck J, Yoshida Y, et al. Buonocore memorial lecture. Adhesion to enamel and dentin: current status and future challenges. *Oper Dent.* 2003;28(3):215–35.
39. Swift EJ Jr, Perdigão J, Heymann HO. Bonding to enamel and dentin: a brief history and state of the art, 1995. *Quintessence Int.* 1995;26(2):95–110.
40. Swift EJ Jr. Dentin bonding: what is the state of the art? *Compend Contin Educ Dent.* 2001;22(12s):4–7.

41. Lafuente JD, Chaves A, Carmiol R. Bond strength of dual-cured resin cements to human teeth. *J Esthet Dent*. 2000;12(2):105–10.
42. Peumans M, De Munck J, Fiehuws S, et al. A prospective ten-year clinical trial of porcelain veneers. *J Adhes Dent*. 2004;6(1):65–76.
43. Christensen GJ. Veneer mania. *J Am Dent Assoc*. 2006;137(8):1161–3.
44. Hikita K, Van Meerbeek B, De Munck J, et al. Bonding effectiveness of adhesive luting agents to enamel and dentin. *Dent Mater*. 2007;23(1):71–80.
45. Ibarra G, Johnson GH, Geurtsen W, Vargas MA. Microleakage of porcelain veneer restorations bonded to enamel and dentin with a new self- adhesive resin-based dental cement. *Dent Mater*. 2007;23(2):218–25.
46. LeSage BP. Revisiting the design of minimal and no-preparation veneers: a step-by-step technique. *J Calif Dent Assoc*. 2010;38(8):561–9.
47. LeSage BP. Minimally invasive dentistry: paradigm shifts in preparation design. *Pract Proced Aesthet Dent*. 2009;21(2):97–101.
48. Magne P, Douglas WH. Porcelain veneers: dentin bonding optimization and biomimetic recovery of the crown. *Int J Prosthodont*. 1999;12(2):111–21.
49. DiMatteo AM. Prep vs no-prep: the evolution of veneers. *Inside Dent*. 2009;5(6):72–9.
50. Gurel G, Sesma N, Calamita MA, Coachman C, Morimoto S. Influence of enamel preservation on failure rates of porcelain laminate veneers. *Int J Periodontics Restorative Dent*. 2013;33:31–9.
51. Giordano R. A comparison of all ceramic systems. *J Mass Dent Soc*. 2002;50(4):16–20.
52. McLaren EA, Cao PT. Ceramics in dentistry – part 1: classes of materials. *Inside Dent*. 2009;5(9):94–103.
53. McLaren EA, LeSage BP. Feldspathic veneers: what are their indications. *Compend Contin Educ Dent*. 2011;32(2):44–9.
54. Morita RK, et al. Minimally invasive laminate veneers: clinical aspects in treatment planning and cementation procedures. *Case Rep Dent*. 2016;2016:1839793.
55. Gürel G. Predictable, precise, and repeatable tooth preparation for porcelain laminate veneers. *Pract Proced Aesthet Dent*. 2003;15(1):17–26.
56. Edelhoff D, Sorensen JA. Tooth structure removal associated with various preparation designs for anterior teeth. *J Prosthet Dent*. 2002;87(5):503–9.
57. Calamia JR, Calamia CS. Porcelain laminate veneers: reasons for 25 years of success. *Dent Clin N Am*. 2007;51(2):399–417.
58. Javaheri D. Considerations for planning esthetic treatment with veneers involving no or minimal preparation. *J Am Dent Assoc*. 2007;138(3):331–7.
59. Brunton PA, Wilson NH. Preparations for porcelain laminate veneers in general dental practice. *Br Dent J*. 1998;184(11):553–6.
60. Rouse JS. Full veneer versus traditional veneer preparation: a discussion of interproximal extension. *J Prosthet Dent*. 1997;78(6):545–9.
61. Chun YH, Raffelt C, Pfeiffer H, et al. Restoring strength of incisors with veneers and full ceramic crowns. *J Adhes Dent*. 2010;12(1):45–54.
62. Stappert CF, Ozden U, Att W, et al. Marginal accuracy of press-ceramic veneers influenced by preparation design and fatigue. *Am J Dent*. 2007;20(6):380–4.
63. Magne P, Belser U. Bonded porcelain restorations in the anterior dentition: a biomimetic approach. Chicago: Quintessence Pub. Co; 2002.
64. Magne P, Douglas WH. Cumulative effects of successive restorative procedures on anterior crown flexure: intact versus veneered incisors. *Quintessence Int*. 2000;31(1):5–18.
65. Peumans M, Van Meerbeek B, Lambrechts P, Vanherle G. Porcelain veneers: a review of the literature. *J Dent*. 2000;28:163–77.
66. McLaren EA, Whiteman YY. Ceramics: rationale for material selection. *Compend Contin Educ Dent*. 2010;31(9):666–80.
67. Andersson GB, Chapman JR, Dekutoski MB, et al. Do no harm: the balance of “beneficence” and “non-maleficence.”. *Spine*. 2010;35(9s):s2–8.